

71. Spies, J. B. (2003). Recovery after uterine artery embolization: Understanding and managing short-term outcomes. *J Vasc Interv Radiol*, Oct;14(10):1219-1222. [http://www.jvir.org/article/S1051-0443\(07\)60259-0/pdf](http://www.jvir.org/article/S1051-0443(07)60259-0/pdf)

72. Spies, J. B., Spector, A., Roth, A. R., et al. (2002). Complications after uterine artery embolization for leiomyomas. *Obstet Gynecol*, Nov;100(5 Pt 1):873-880. <https://www.ncbi.nlm.nih.gov/pubmed/12423844>

73. Spies, J. B., Benenati, J. F., Worthington-Kirsch, R. L., et al. (2001). Initial experience with use of tris-acryl gelatin microspheres for uterine artery embolization for leiomyoma. *J Vasc Interv Radiol*, Sep;12(9):1059-1063. <https://www.ncbi.nlm.nih.gov/pubmed/11535768>

74. Stampfl, S., Stampfl, U., Bellemann, N., et al. (2009). Immunohistochemical characterization of specific inflammatory tissue reactions following embolization with four different spherical agents in the minipig kidney model. *J Vasc Interv Radiol*, Jul;20(7):936-945. <https://www.ncbi.nlm.nih.gov/pubmed/19555888>

75. Stampfl, S., Bellemann, N., Stampfl, U., et al. (2009). Arterial distribution characteristics of Embozene particles and comparison with other spherical embolic agents in the porcine acute embolization model. *J Vasc Interv Radiol*, Dec;20(12):1597-1607. <https://www.ncbi.nlm.nih.gov/pubmed/19944985>

76. Stampfl, S., Bellemann, N., Stampfl, U., et al. (2008). Inflammation and recanalization of four different spherical embolization agents in the porcine kidney model. *J Vasc Interv Radiol*, Apr;19(4):577-586. <https://www.ncbi.nlm.nih.gov/pubmed/18375304>

77. Sutter, O., Soyer, P., Shotar, E., et al. (2016). Diffusion-weighted MR imaging of uterine leiomyomas following uterine artery embolization. *Eur Radiol*, Oct;26(10):3558-3570. <https://www.ncbi.nlm.nih.gov/pubmed/26801165>

78. Torre, A., Fauconnier, A., Kahn, V., et al. (2017). Fertility after uterine artery embolization for symptomatic multiple fibroids with no other infertility factors. *Eur Radiol*, Jul;27(7):2850-2859. <https://www.ncbi.nlm.nih.gov/pubmed/27966042>

79. Torre, A., Paillusson, B., Fain, V., et al. (2014). Uterine artery embolization for severe symptomatic fibroids: Effects on fertility and symptoms. *Hum Reprod*, Mar;29(3):490-501. <https://www.ncbi.nlm.nih.gov/pubmed/24430777>

This bibliography is a partial list of published journal articles; it is not all inclusive.

#### REFERENCES

- Siskin G, Beck A, Schuster M., et al. (2008). Leiomyoma infarction after uterine artery embolization: a prospective randomized study comparing tris-acryl gelatin microspheres versus polyvinyl alcohol microspheres. *J Vasc Interv Radiol*, Jan;19(1):58-65. <https://www.ncbi.nlm.nih.gov/pubmed/18192468>
- Duvnjak S, Ravn P, Green A., et al. (2017). Assessment of uterine fibroid infarction after embolization with tris-acryl gelatin microspheres. *Cogent Med*, Aug;4(1):1360543. <http://www.tandfonline.com/doi/full/10.1080/2331205X.2017.1360543>
- Spies J. B., Allison S., Flick P., et al. (2005). Spherical polyvinyl alcohol versus tris-acryl gelatin microspheres for uterine artery embolization for leiomyomas: Results of a limited randomized comparative study. *J Vasc Interv Radiol*, Nov;16(11):1431-1437. <https://www.ncbi.nlm.nih.gov/pubmed/16319148>
- Shlansky-Goldberg R. D., Rosen M. A., Mondschein J. I., et al. (2014). Comparison of polyvinyl alcohol microspheres and tris-acryl gelatin microspheres for uterine fibroid embolization: Results of a single-center randomized study. *J Vasc Interv Radiol*, Jun;25(6):823-832. <https://www.ncbi.nlm.nih.gov/pubmed/24788209>
- Jean Pierre Pelage, MD. (2005). Perfusion of Uterine Fibroids after arterial Embolization is a Predictor of Clinical Outcome. Society of Interventional Radiology abstract.
- Katsumori T, Kasahara T, Kin Y., et al. (2008). Infarction of uterine fibroids after embolization: relationship between postprocedural enhanced MRI findings and long-term clinical outcomes. *Cardiovasc Intervent Radiol*, Jan-Feb;31(1):66-72. <https://www.ncbi.nlm.nih.gov/pubmed/17943351>
- Kroencke T. J., Scheurig C., Poellinger A., et al. (2010). Uterine artery embolization for leiomyomas: percentage of infarction predicts clinical outcome. *Radiology*, Jun;255(3):834-41. <https://www.ncbi.nlm.nih.gov/pubmed/20392986>
- Smeets A. J., Nijenhuis R. J., van Rooij W. J., et al. (2010). Embolization of uterine leiomyomas with polyvone F-coated hydrogel microspheres: initial experience. *J Vasc Interv Radiol*, Dec;21(12):1830-4. <https://www.ncbi.nlm.nih.gov/pubmed/21111364>
- Chrisman H. B., Dhand S., Rajeswaran S., et al. (2010). Prospective evaluation of the embolic agent Bead Block in the treatment of uterine leiomyomas with uterine artery embolization. *J Vasc Interv Radiol*, Apr;21(4):484-9. <https://www.ncbi.nlm.nih.gov/pubmed/20149690>
- Searched pubmed.gov and Google Scholar for the following keywords and combinations: "uterine artery embolization", "UFE", "HydroPearl", "GelBead", "OptiSphere", "uterine artery embolization", "UAE", "leiomyomas", "uterine fibroid infarction", "UFE".



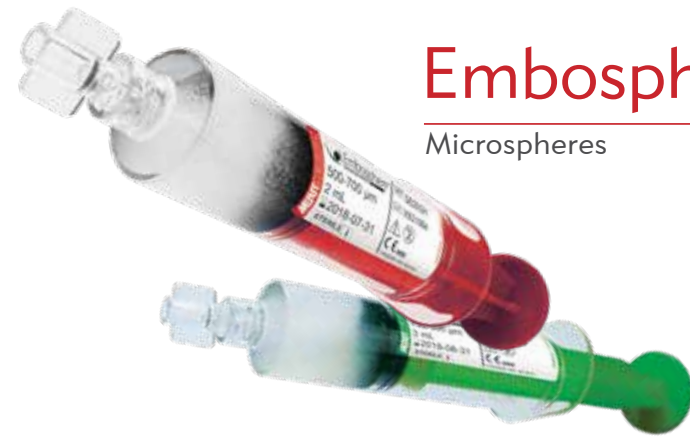
Understand. Innovate. Deliver.™

Merit Medical Systems, Inc.  
1600 West Merit Parkway  
South Jordan, Utah 84095  
1.801.208.4300  
1.800.35.MERIT

Merit Medical Europe, Middle East, & Africa (EMEA)  
Amerikalaan 42, 6199 AE Maastricht-Airport  
The Netherlands  
+31 43 358 82 22

Merit Medical Ireland Ltd.  
Parkmore Business Park West  
Galway, Ireland  
+353 (0) 91 703 733

Merit.com



# Embosphere®

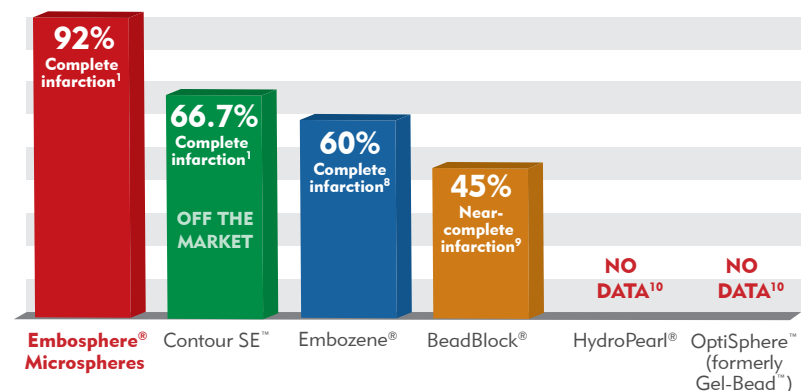
## Microspheres

## PROVEN SUPERIOR PERFORMANCE

Embosphere® is the only microsphere to consistently demonstrate high infarction rates of all fibroids<sup>1-4</sup>

Because ≥90% infarction of all fibroids leads to long-term symptom control and a significantly lower rate of reintervention<sup>5-7</sup>, Embosphere is the clear choice for uterine fibroid embolization. Embosphere is the only microsphere to consistently yield high infarction rates and provide reliable results for more than 20 years.

Percentage of Patients with Complete Infarction (100%) of Entire Uterine Fibroid Tumor Burden



# UFE BIBLIOGRAPHY

1. Abramowitz, S. D., Israel, G. M., McCarthy, S. M., et al. (2009). Comparison of four embolic materials at uterine artery embolization by using postprocedural MR imaging enhancement. *Radiology*, Feb;250(2):482-487. <https://www.ncbi.nlm.nih.gov/pubmed/19188316>
2. Baker, C. M., Winkel, C. A., Subramanian, S., et al. (2002). Estimated costs for uterine artery embolization and abdominal myomectomy for uterine leiomyomata: A comparative study at a single institution. *J Vasc Interv Radiol*, Dec;13(12):1207-1210. <https://www.ncbi.nlm.nih.gov/pubmed/12471183>
3. Banovac, F., Ascher, S. M., Jones, D. A., et al. (2002). Magnetic resonance imaging outcome after uterine artery embolization for leiomyomata with use of tris-acryl gelatin microspheres. *J Vasc Interv Radiol*, Jul;13(7):681-688. <https://www.ncbi.nlm.nih.gov/pubmed/12119326>
4. Bao, G., Hu, L., Charles, H. W., et al. (2017). Ineffectiveness of magnetic resonance imaging enhancement to predict fibroid volume reduction after uterine artery embolization. *Proc (Bayl Univ Med Cent)*, Jul;30(3):259-261. <https://www.ncbi.nlm.nih.gov/pmc/articles/PMC5468007/>
5. Barnard, E. P., AbdElmagied, A. M., Vaughan, L. E., et al. (2017). Periprocedural outcomes comparing fibroid embolization and focused ultrasound: A randomized controlled trial and comprehensive cohort analysis. *Am J Obstet Gynecol*, May;216(5):500.e1-500.e11. <https://www.ncbi.nlm.nih.gov/pubmed/28063909>
6. Bilbao, J. I., de Luis, E., García de Jalón, J. A., et al. (2008). Comparative study of four different spherical embolic particles in an animal model: A morphologic and histologic evaluation. *J Vasc Interv Radiol*, Nov;19(11):1625-1638. <https://www.ncbi.nlm.nih.gov/pubmed/18823795>
7. Binkert, C. A., Hirzel, F. C., Gutzeit, A., et al. (2015). Superior hypogastric nerve block to reduce pain after uterine artery embolization: Advanced technique and comparison to epidural anesthesia. *Cardiovasc Intervent Radiol*, Oct;38(5):1157-1161. <https://www.ncbi.nlm.nih.gov/pubmed/25975741>
8. Binkert, C. A., Andrews, R. T., Pavcnik, D., et al. (2002). Lack of suitability of the rabbit model for particulate uterine artery embolization. *J Vasc Interv Radiol*, Jun;13(6):609-612. <https://www.ncbi.nlm.nih.gov/pubmed/12050301>
9. de Blok, S., de Vries, C., Prinszen, H. M., et al. (2003). Fatal sepsis after uterine artery embolization with microspheres. *J Vasc Interv Radiol*, Jun;14(6):779-783. <https://www.ncbi.nlm.nih.gov/pubmed/12817046>
10. Broder, M. S., Goodwin, S., Chen, G., et al. (2002). Comparison of long-term outcomes of myomectomy and uterine artery embolization. *Obstet Gynecol*, Nov;100(5 Pt 1):864-868. <https://www.ncbi.nlm.nih.gov/pubmed/12423842>
11. Bruno, J., Sterbis, K., Flick, P., et al. (2004). Recovery after uterine artery embolization for leiomyomas: A detailed analysis of its duration and severity. *J Vasc Interv Radiol*, Aug;15(8):801-807. <https://www.ncbi.nlm.nih.gov/pubmed/15297583>
12. Chiesa, A. G., & Hart, W. R. (2004). Uterine artery embolization of leiomyomas with trisacryl gelatin microspheres (TGM): Pathologic features and comparison with polyvinyl alcohol emboli. *Int J Gynecol Pathol*, Oct;23(4):386-392. <https://www.ncbi.nlm.nih.gov/pubmed/15381909>
13. Chua, G. C., Wilsher, M., Young, M. P., et al. (2005). Comparison of particulate penetration with non-spherical polyvinyl alcohol versus trisacryl gelatin microspheres in women undergoing premyomectomy uterine artery embolization. *Clin Radiol*, Jun;60(1):116-122. <https://www.ncbi.nlm.nih.gov/pmid/15642302/>
14. Duvnjak, S., Ravn, P., Green, A., et al. (2017). Assessment of uterine fibroid infarction after embolization with tris-acryl gelatin microspheres. *Cogent Med*, Aug;4(1):1360543. <http://www.tandfonline.com/doi/full/10.1080/2331205X.2017.1360543>
15. Elsarraig, S. Z., Fors, A. R., Richman, S., et al. (2015). Acute ovarian insufficiency and uterine infarction following uterine artery embolization for postpartum hemorrhage. *Clin Med Res Case Rep*, Jun;2(2):040. <https://www.ncbi.nlm.nih.gov/pubmed/26523290>
16. Fidelman, N., Wilson, M. W., Weber, O. M., et al. (2002). Real-time MR properties of particulate embolic agents tested in a dynamic flow model. *J Vasc Interv Radiol*, Jun;13(6):613-618. <https://www.ncbi.nlm.nih.gov/pubmed/12050302>
17. Fogt, F., Hinds, N., & Zimmerman, R. L. (2003). Histologic features of uterine leiomyomata treated with microsphere embolization. *Obstet Gynecol*, Sep;102(3):600-602. <https://www.ncbi.nlm.nih.gov/pubmed/12962949>
18. Galvez, J. A., McCarthy, S., Weinreb, J., et al. (2008). Comparison of MRI outcomes of uterine artery embolization for uterine leiomyoma using tris-acryl gelatin microspheres, polyvinyl alcohol spheres, and polyvinyl alcohol particles. *J Comput Assist Tomogr*, May-Jun;32(3):356-361. <https://www.ncbi.nlm.nih.gov/pubmed/18520537>
19. Gopal, M., Goldberg, J., Klein, T. A., et al. (2003). Embolization of a uterine arteriovenous malformation followed by a twin pregnancy. *Obstet Gynecol*, Oct;102(4):696-698. <https://www.ncbi.nlm.nih.gov/pubmed/14550998>
20. Henri, M., Florence, E., Aurore, B., et al. (2014). Contribution of contrast-enhanced ultrasound with Sonovue to describe the microvascularization of uterine fibroid tumors before and after uterine artery embolization. *Eur J Obstet Gynecol Reprod Biol*, Oct;181:104-110. <https://www.ncbi.nlm.nih.gov/pubmed/25137658>
21. Hovsepian, D. M., Ratts, V. S., Rodriguez, M., et al. (2006). A prospective comparison of the impact of uterine fibroid embolization, myomectomy, and hysterectomy on ovarian function. *J Vasc Interv Radiol*, Jul;17(7):1111-1115. <https://www.ncbi.nlm.nih.gov/pubmed/16868163>
22. Kim, H. S., Tsai, J., Lee, J. M., et al. (2006). Effects of utero-ovarian anastomoses on basal follicle-stimulating hormone level change after uterine artery embolization with tris-acryl gelatin microspheres. *J Vasc Interv Radiol*, Jun;17(6):965-971. <https://www.ncbi.nlm.nih.gov/pubmed/16778229>
23. Joffe, F., Tubiana, J. M., Pelage, J. P., et al. (2004). FEMIC (Fibromes Embolisés aux Microsphères Calibrées): Uterine fibroid embolization using tris-acryl microspheres. A French multicenter study. *Cardiovasc Intervent Radiol*, Nov-Dec;27(6):600-606. <https://www.ncbi.nlm.nih.gov/pubmed/15578135>
24. Katsumori, T., Miura, H., Suzuki, G., et al. (2015). Angiographic endpoint using "artificial flow" on uterine artery embolization for leiomyomas in the circumstance with no free flow in uterine artery. *Cardiovasc Intervent Radiol*, Aug;38(4):1047-1049. <https://www.ncbi.nlm.nih.gov/pubmed/25910969>
25. Koesters, C., Powserski, M. J., Froelung, V., et al. (2014). Uterine artery embolization in single symptomatic leiomyoma: Do anatomical imaging criteria predict clinical presentation and long-term outcome? *Acta Radiol*, May;55(4):441-449. <https://www.ncbi.nlm.nih.gov/pubmed/23943627>
26. Kohlbrenner, R., Kolli, K. P., Taylor, A. G., et al. (2017). Radiation dose reduction during uterine fibroid embolization using an optimized imaging platform. *J Vasc Interv Radiol*, Aug;28(8):1129-1135. <https://www.ncbi.nlm.nih.gov/pubmed/28457758>
27. Kroencke, T. J., Scheurig, C., Poellinger, A., et al. (2010). Uterine artery embolization for leiomyomas: Percentage of infarction predicts clinical outcome. *Radiology*, Jun;255(3):834-841. <https://www.ncbi.nlm.nih.gov/pubmed/20392986>
28. Lacayo, E. A., Richman, D. L., Acord, M. R., et al. (2017). Leiomyoma infarction after uterine artery embolization: Influence of embolic agent and leiomyoma size and location on outcome. *J Vasc Interv Radiol*, Jul;28(7):1003-1010. <https://www.ncbi.nlm.nih.gov/pubmed/28479027>
29. Laios, A., Baharuddin, N., Iliou, K., et al. (2014). Uterine artery embolization for treatment of symptomatic fibroids: a single institution experience. *Hippokratia*, Jul-Sep;18(3):258-261. <https://www.ncbi.nlm.nih.gov/pubmed/25694762>
30. Latif, E., Adam, S., Rungruang, B., et al. (2016). Use of uterine artery embolization to prevent peripartum hemorrhage of placental abruption with fetal demise & severe DIC. *J Neonatal Perinatal Med*, Sep;9(3):325-331. <https://www.ncbi.nlm.nih.gov/pubmed/27589544>
31. Laurent, A., Wassef, M., Namur, J., et al. (2009). Recanalization and particle exclusion after embolization of uterine arteries in sheep: A long-term study. *Fertil Steril*, Mar;91(3):884-892. <https://www.ncbi.nlm.nih.gov/pubmed/18321492>
32. Laurent, A., Wassef, M., Saint Maurice, J. P., et al. (2006). Arterial distribution of calibrated tris-acryl gelatin and polyvinyl alcohol microspheres in a sheep kidney model. *Invest Radiol*, Jan;41(1):8-14. <https://www.ncbi.nlm.nih.gov/pubmed/16355034>
33. Laurent, A., Beaujeux, R., Wassef, M., et al. (1996). Trisacryl gelatin microspheres for therapeutic embolization. I: Development and in vitro evaluation. *ANJR Am J Neuroradiol*, Mar;17(3):533-540. <https://www.ncbi.nlm.nih.gov/pubmed/8881250>
34. Lefebvre, G. G., Vilos, G., Asch, M., et al. (2004). Uterine fibroid embolization (UFE). *J Obstet Gynaecol Can*, Oct;26(10):899-911, 913-928. <https://www.ncbi.nlm.nih.gov/pubmed/15507201>
35. Lewis, A. L., Adams, C., Busby, W., et al. (2006). Comparative in vitro evaluation of microspherical embolisation agents. *J Mater Sci Mater Med*, Dec;17(12):1193-1204. <https://www.ncbi.nlm.nih.gov/pubmed/17143749>
36. Liaw, J. V., Yun, C. H., Walker, T. G., et al. (2012). Comparison of clinical and MR imaging outcomes after uterine fibroid embolization with Bead Block and Embosphere. *Eur J Radiol*, Jun;81(6):1371-1375. <https://www.ncbi.nlm.nih.gov/pubmed/21439744>
37. Lohle, P. N., Boekkooy, F. P., Smeets, A. J., et al. (2006). Limited uterine artery embolization for leiomyomas with tris-acryl gelatin microspheres: 1-year follow-up. *J Vasc Interv Radiol*, Feb;17(2 Pt 1):283-287. <https://www.ncbi.nlm.nih.gov/pubmed/16517773>
38. Lohle, P. N., Voogt, M. J., De Vries, J., et al. (2008). Long-term outcome of uterine artery embolization for symptomatic uterine leiomyomas. *J Vasc Interv Radiol*, Mar;19(3):319-326. <https://www.ncbi.nlm.nih.gov/pubmed/18295689>
39. Lohle, P. N., De Vries, J., Klazen, C. A., et al. (2007). Uterine artery embolization for symptomatic adenomyosis with or without uterine leiomyomas with the use of calibrated tris-acryl gelatin microspheres: Midterm clinical and MR imaging follow-up. *J Vasc Interv Radiol*, Jul;18(7):835-841. <https://www.ncbi.nlm.nih.gov/pubmed/17609441>
40. Macnaught, G., Ananthakrishnan, G., Hinksman, L., et al. (2016). Can (1)H MR spectroscopy be used to assess the success of uterine artery embolization? *Cardiovasc Intervent Radiol*, Mar;39(3):376-384. <https://www.ncbi.nlm.nih.gov/pubmed/26183465>
41. Malartic, C., Morel, O., Fargeaudou, Y., et al. (2012). Conservative two-step procedure including uterine artery embolization with Embosphere and surgical myomectomy for the treatment of fibroids: Preliminary experience. *Eur J Radiol*, Jan;81(1):1-5. <https://www.ncbi.nlm.nih.gov/pubmed/21112709>
42. Marret, H., Alonso, A. M., Cottier, J. P., et al. (2003). Leiomyoma recurrence after uterine artery embolization. *J Vasc Interv Radiol*, Nov;14(11):1395-1399. <https://www.ncbi.nlm.nih.gov/pubmed/14605104>
43. Marx, M., Wack, J. P., Baker, E. L., et al. (2003). Ovarian protection by occlusion of uteroovarian collateral vessels before uterine fibroid embolization. *J Vasc Interv Radiol*, Oct;14(10):1329-1332. [http://www.jvir.org/article/S1051-0443\(07\)60274-7/fulltext](http://www.jvir.org/article/S1051-0443(07)60274-7/fulltext)
44. Myers, E., Goodwin, S., Landow, W., et al. (2005). Prospective data collection of a new procedure by a specialty society: The FIBROID Registry. *Obstet Gynecol*, Jul;106(1):44-51. <https://www.ncbi.nlm.nih.gov/pubmed/15994616>
45. Nikolic, B., Nguyen, K., Martin, L. G., et al. (2004). Pyosalpinx developing from a preexisting high uterine artery uterine artery embolization. *J Vasc Interv Radiol*, Mar;15(3):297-301. <https://www.ncbi.nlm.nih.gov/pubmed/15028817>
46. Nikolic, B., Kessler, C. M., Jacobs, H. M., et al. (2003). Changes in blood coagulation markers associated with uterine artery embolization for leiomyomata. *J Vasc Interv Radiol*, Sep;14(9 Pt 1):1147-1153. [http://www.jvir.org/article/S1051-0443\(07\)60528-4/pdf](http://www.jvir.org/article/S1051-0443(07)60528-4/pdf)
47. Obele, C. C., Dunham, S., Bennett, G., et al. (2016). A case of pyomyoma following uterine fibroid embolization and a review of the literature. *Case Rep Obstet Gynecol*, 2016:9835412. <https://www.ncbi.nlm.nih.gov/pubmed/27066283>
48. Payne, J. F., Robboy, S. J., Haney, A. F., et al. (2002). Embolic microspheres within ovarian arterial vasculature after uterine artery embolization. *Obstet Gynecol*, Nov;100(5 Pt 1):883-886. <https://www.ncbi.nlm.nih.gov/pubmed/12423846>
49. Pelage, J. P. (2004). Polyvinyl alcohol particles versus tris-acryl gelatin microspheres for uterine artery embolization for leiomyomas. *J Vasc Interv Radiol*, Aug;15(8):789-791. <https://www.ncbi.nlm.nih.gov/pubmed/15297581>
50. Pelage, J. P., Le Dref, O., Beregi, J. P., et al. (2003). Limited uterine artery embolization with tris-acryl gelatin microspheres for uterine fibroids. *J Vasc Interv Radiol*, Jan;14(1):15-20. <https://www.ncbi.nlm.nih.gov/pubmed/12525582>
51. Pelage, J. P., Laurant, A., Wassef, M., et al. (2002). Uterine artery embolization in sheep: Comparison of acute effects with polyvinyl alcohol particles and calibrated microspheres. *Radiology*, Aug;224(2):436-445. <https://www.ncbi.nlm.nih.gov/pubmed/12147840>
52. Pinto Pabón, I., Magret, J. P., Unzurrunzaga, E. A., et al. (2008). Pregnancy after uterine fibroid embolization: Follow-up of 100 patients embolized using tris-acryl gelatin microspheres. *Fertil Steril*, Dec;90(6):2356-60. <https://www.ncbi.nlm.nih.gov/pubmed/18339388>
53. Rajan, D. K., Becroft, J. R., Clark, T. W., et al. (2004). Risk of intrauterine infectious complications after uterine artery embolization. *J Vasc Interv Radiol*, Dec;15(12):1415-1421. <https://www.ncbi.nlm.nih.gov/pubmed/15590799>
54. Razavi, M. K., Wolanske, K. A., Hwang, G. L., et al. (2002). Angiographic classification of ovarian artery-to-uterine artery anastomoses: Initial observations in uterine fibroid embolization. *Radiology*, Sep;224(3):707-712. <https://www.ncbi.nlm.nih.gov/pubmed/12202703>
55. Resnick, N. J., Kim, E., Patel, R. S., et al. (2014). Uterine artery embolization using a transradial approach: Initial experience and technique. *J Vasc Interv Radiol*, Mar;25(3):443-447. <https://www.ncbi.nlm.nih.gov/pubmed/24581468>
56. Richter, G. M., Radeleff, B., Rimbach, S., et al. (2004). Uterine fibroid embolization with spheric micro-particles using flow guiding: Safety, technical success and clinical results. *Rofo*, Nov;176(11):1648-1657. <https://www.ncbi.nlm.nih.gov/pubmed/15497084>
57. Rott, G., & Boecker, F. (2016). The extremely rare vascular variant of a segmental duplicated uterine artery and its relevance for the interventionalist and gynecologist: A case report. *J Med Case Rep*, Jun;10:162. <https://www.ncbi.nlm.nih.gov/pmc/articles/PMC4893218/>
58. Ryan, J. M., Gainey, M., Glasson, J., et al. (2002). Simplified pain-control protocol after uterine artery embolization. *Radiology*, Aug;224(2):610-611; discussion 611-613. <https://www.ncbi.nlm.nih.gov/pubmed/12147865>
59. Ryu, R. K. (2005). Uterine artery embolization: Current implications of embolic choice. *J Vasc Interv Radiol*, Nov;16(11):1419-1422. <https://www.ncbi.nlm.nih.gov/pubmed/16319145>
60. Ryu, R. K., Omary, R. A., & Sichelau, M. J. (2003). Comparison of pain after uterine artery embolization using tris-acryl gelatin microspheres versus polyvinyl alcohol particles. *Cardiovasc Intervent Radiol*, Jul-Aug;26(4):375-378. <https://www.ncbi.nlm.nih.gov/pubmed/14667120>
61. Ryu, R. K., Chrisman, H. B., Omary, R. A., et al. (2001). The vascular impact of uterine artery embolization: Prospective sonographic assessment of ovarian arterial circulation. *J Vasc Interv Radiol*, Sep;12(9):1071-1074. <https://www.ncbi.nlm.nih.gov/pubmed/11535770>
62. Scheurig-Muenkler, C., Powserski, M. J., Mueller, J. C., et al. (2015). Radiation exposure during uterine artery embolization: Effective measures to minimize dose to the patient. *Cardiovasc Intervent Radiol*, Jun;38(3):613-622. <https://www.ncbi.nlm.nih.gov/pubmed/25148920>
63. Shlansky-Goldberg, R. D., Rosen, M. A., Mondschein, J. I., et al. (2014). Comparison of polyvinyl alcohol microspheres and tris-acryl gelatin microspheres for uterine fibroid embolization: Results of a single-center randomized study. *J Vasc Interv Radiol*, Jun;25(6):823-832. <https://www.ncbi.nlm.nih.gov/pubmed/24788209>
64. Siskin, G. P., Beck, A., Schuster, M., et al. (2008). Leiomyoma infarction after uterine artery embolization: A prospective randomized study comparing tris-acryl gelatin microspheres versus polyvinyl alcohol microspheres. *J Vasc Interv Radiol*, Jan;19(1):58-65. <https://www.ncbi.nlm.nih.gov/pubmed/18192468>
65. Siskin, G. P., Dowling, K., Virmani, R., et al. (2003). Pathologic evaluation of a spherical polyvinyl alcohol embolic agent in a porcine renal model. *J Vasc Interv Radiol*, Jan;14(1):89-98. <https://www.ncbi.nlm.nih.gov/pubmed/12525592>
66. Smeets, A. J., Lohle, P. N., Vervest, H. A., et al. (2006). Mid-term clinical results and patient satisfaction after uterine embolization in women with symptomatic uterine fibroids. *Cardiovasc Intervent Radiol*, Mar-Apr;29(2):188-91. <https://www.ncbi.nlm.nih.gov/pubmed/16195836>
67. Spies, J. B., Cornell, C., Worthington-Kirsch, R., et al. (2007). Long-term outcome from uterine fibroid embolization with tris-acryl gelatin microspheres: Results of a multicenter study. *J Vasc Interv Radiol*, Feb;18(2):203-207. <https://www.ncbi.nlm.nih.gov/pubmed/17327552>
68. Spies, J. B., Allison, S., Flick, P., et al. (2005). Spherical polyvinyl alcohol versus tris-acryl gelatin microspheres for uterine artery embolization for leiomyomas: Results of a limited randomized comparative study. *J Vasc Interv Radiol*, Nov;16(11):1431-1437. <https://www.ncbi.nlm.nih.gov/pubmed/16319148>
69. Spies, J. B., Allison, S., Flick, P., et al. (2004). Polyvinyl alcohol particles and tris-acryl gelatin microspheres for uterine artery embolization for leiomyomas: Results of a randomized comparative study. *J Vasc Interv Radiol*, Aug;15(8):793-800. <https://www.ncbi.nlm.nih.gov/pubmed/15297582>
70. Spies, J. B. (2003). Uterine artery embolization for fibroids: Understanding the technical causes of failure. *J Vasc Interv Radiol*, Jan;14(1):11-14. <https://www.ncbi.nlm.nih.gov/pubmed/12525581>